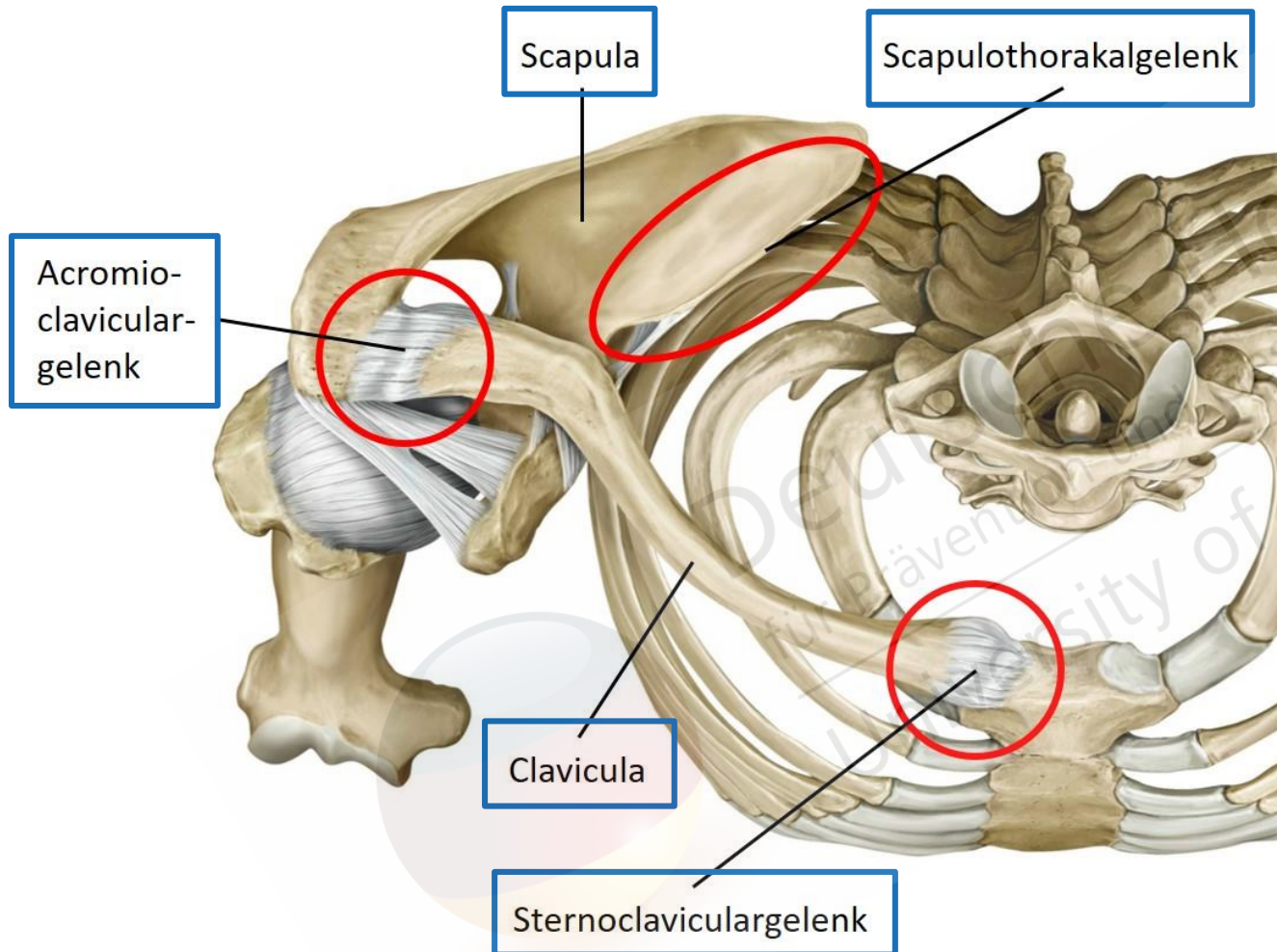


Der Schultergürtel



Gilroy, Atlas of Anatomy, 1st ed., Abb. 19.7, Illustrator: Karl Wesker,
©2020 Thieme Medical Publishers, Inc. All Rights Reserved.

Teilgelenke:

Acromioclaviculargelenk
Sternoclaviculargelenk
Scapulothorakalgelenk

Gelenkbildende Knochen:

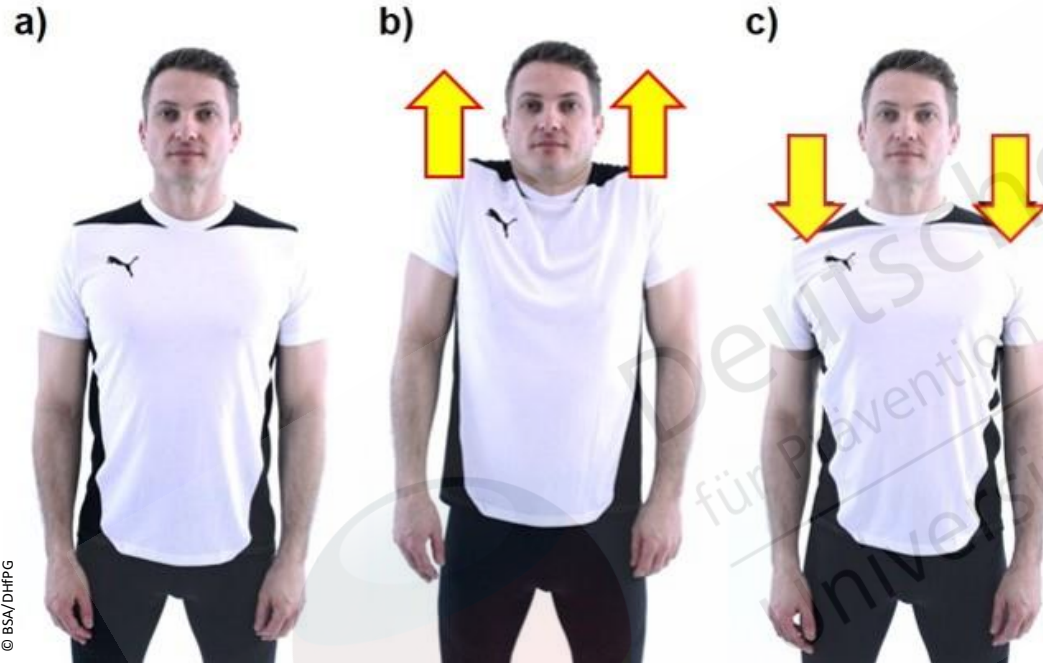Schulterblatt
Schlüsselbein

Bewegungsmöglichkeiten:

Elevation – Depression
Retraktion – Protraktion

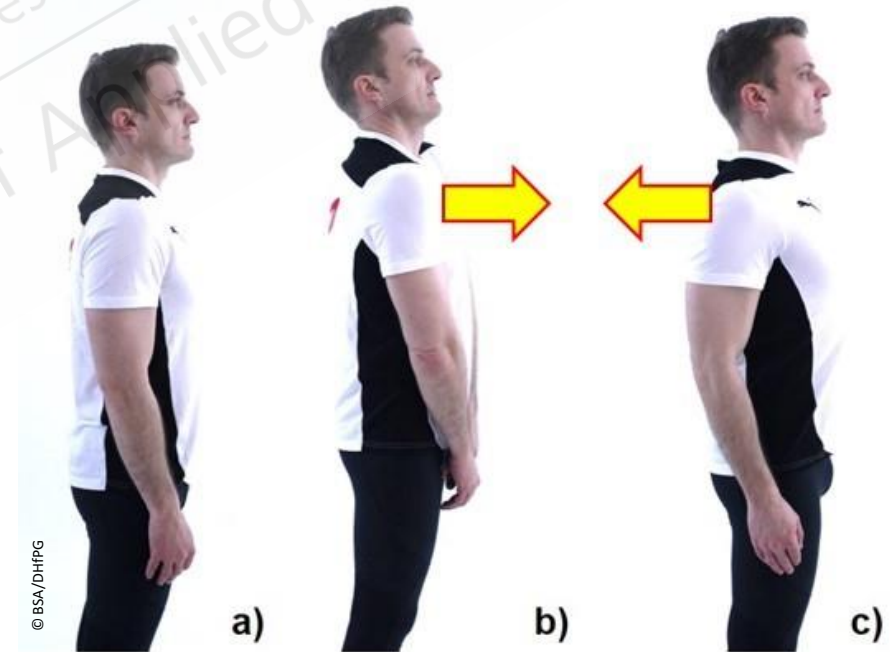
Bewegungen des Schultergürtels

Elevation – Depression



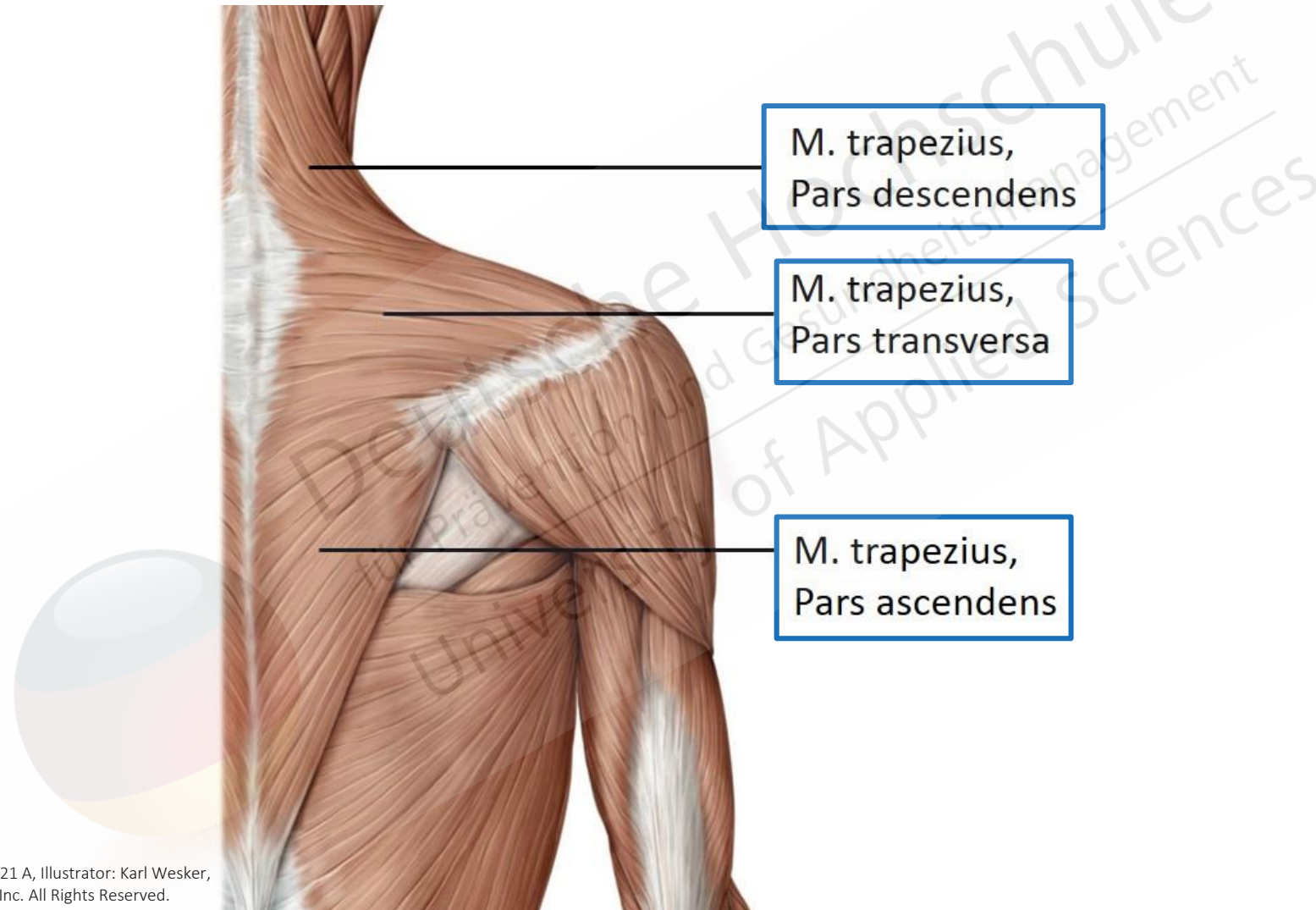
© BSA/DHHPG

Protraktion – Retraktion



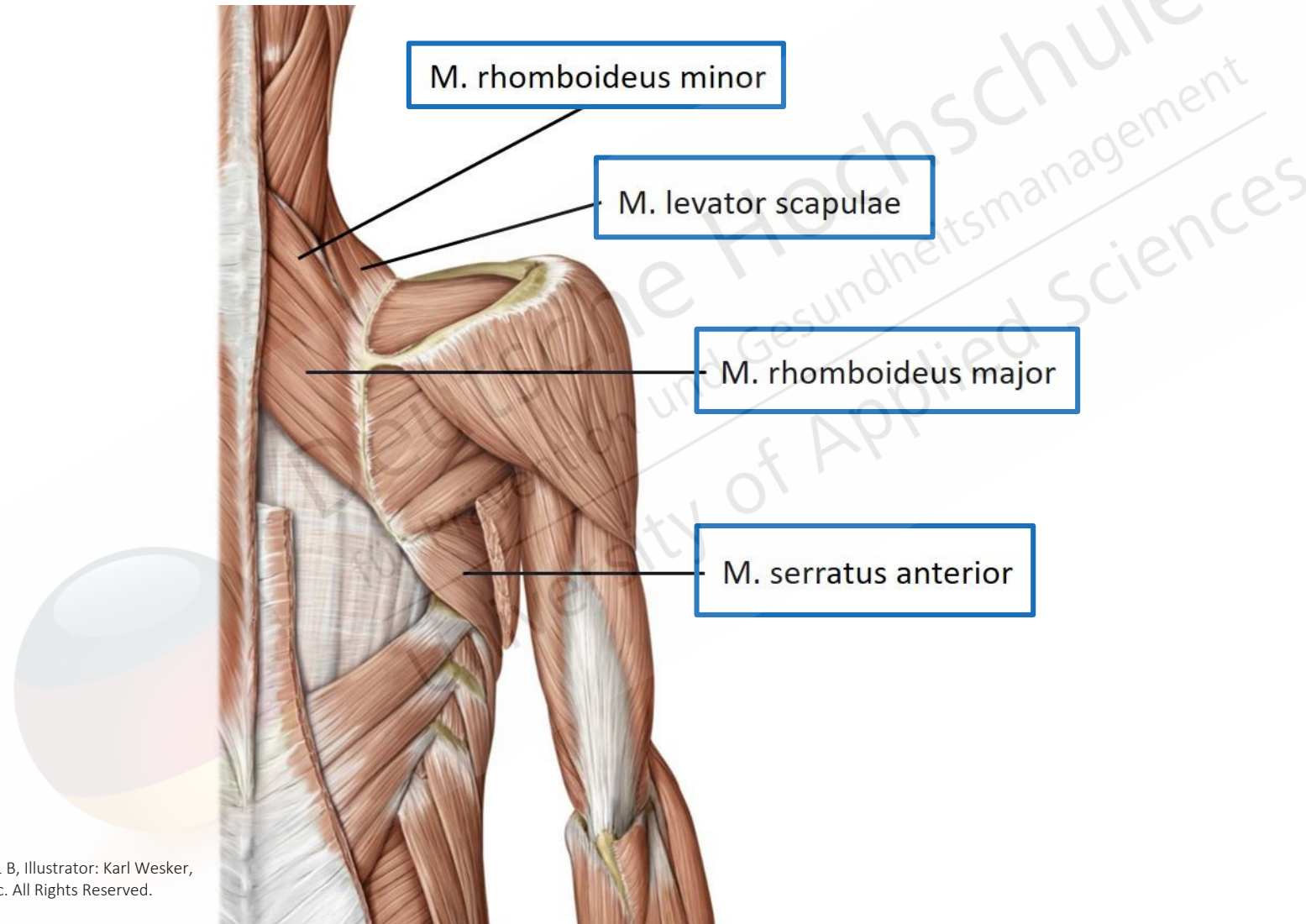
© BSA/DHHPG

Muskulatur des Schultergürtels – Ansicht von dorsal



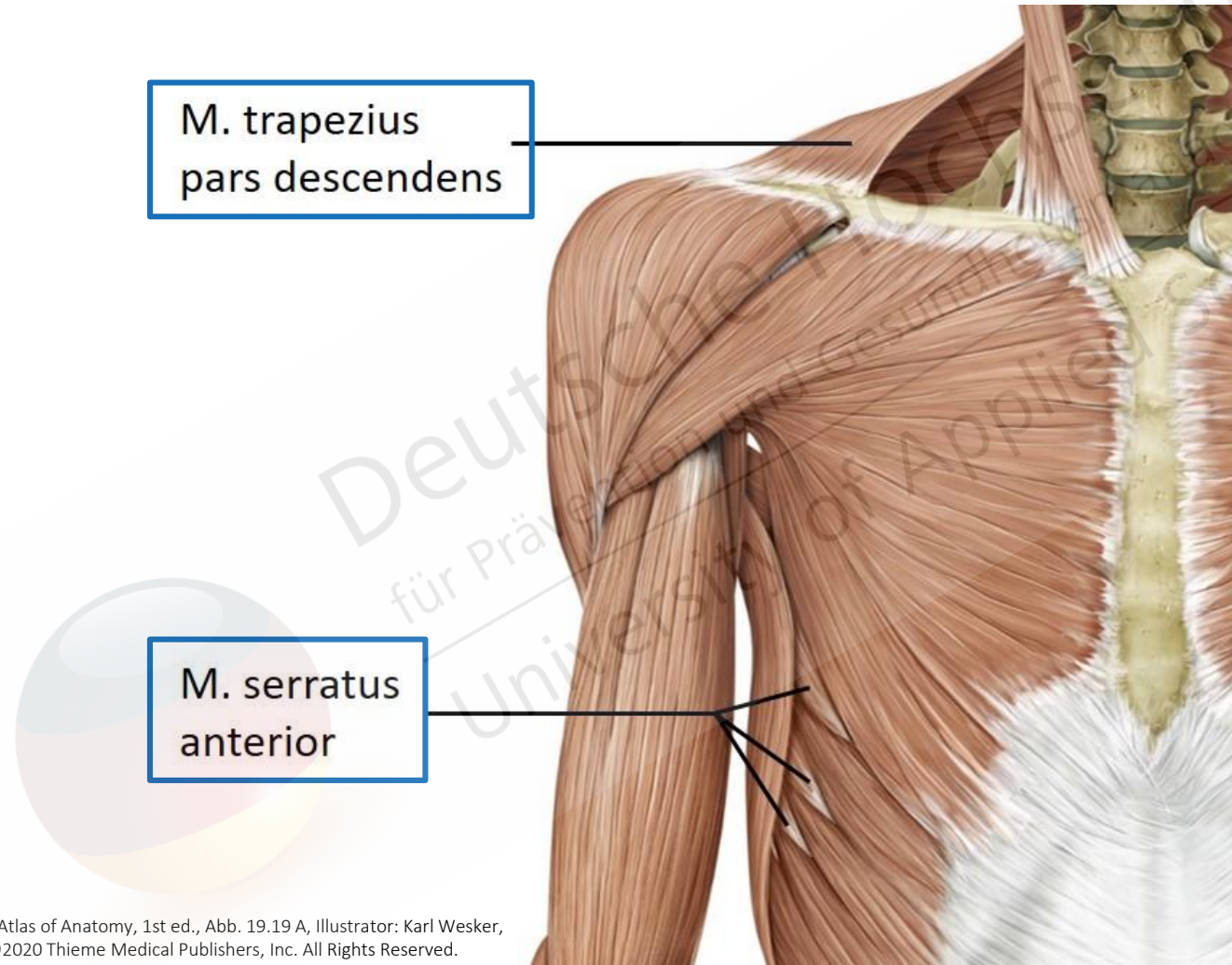
Gilroy, Atlas of Anatomy, 1st ed., Abb. 19.21 A, Illustrator: Karl Wesker,
©2020 Thieme Medical Publishers, Inc. All Rights Reserved.

Muskulatur des Schultergürtels – Ansicht von dorsal



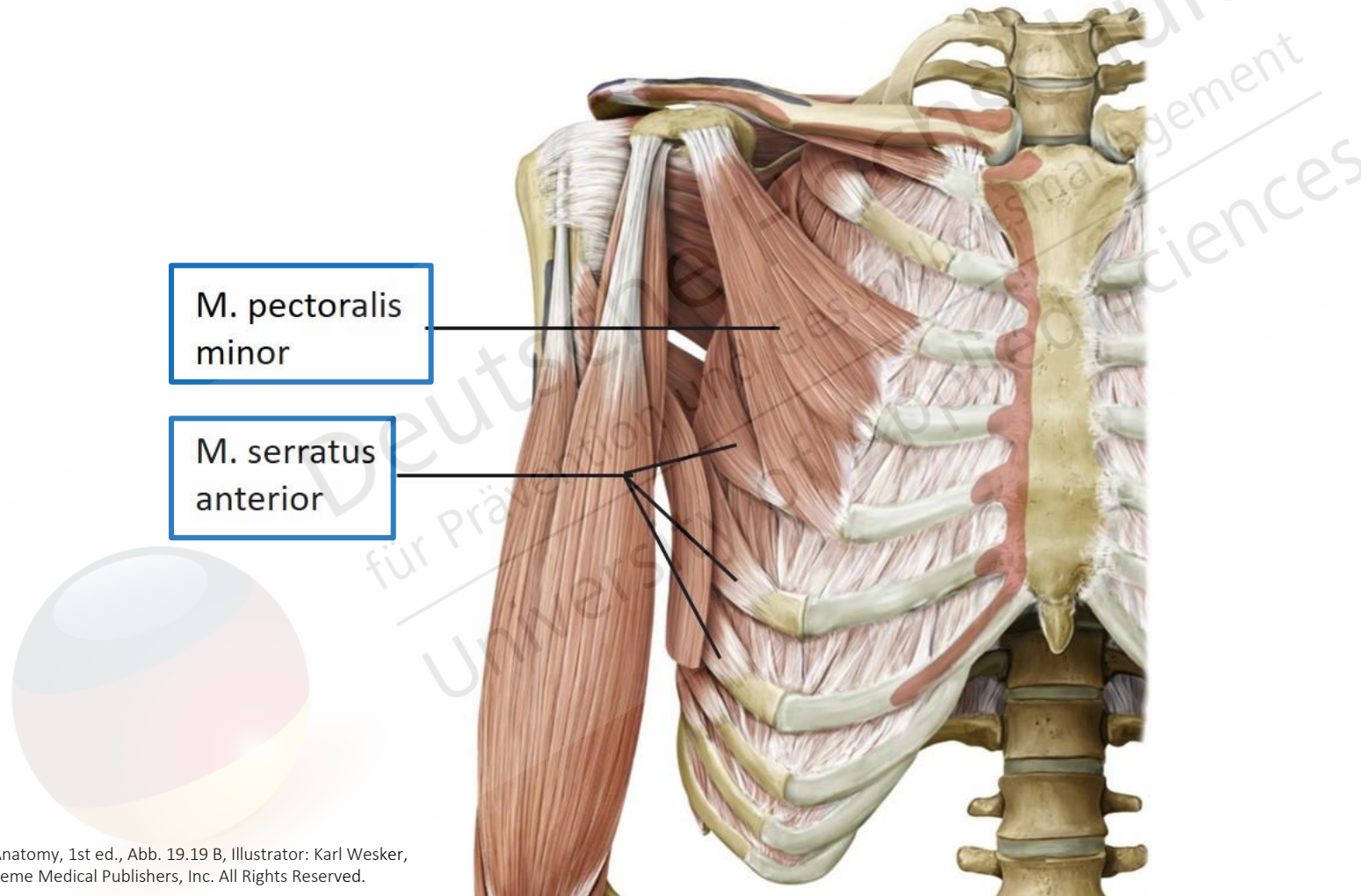
Gilroy, Atlas of Anatomy, 1st ed., Abb. 19.21 B, Illustrator: Karl Wesker,
©2020 Thieme Medical Publishers, Inc. All Rights Reserved.

Muskulatur des Schultergürtels – Ansicht von ventral



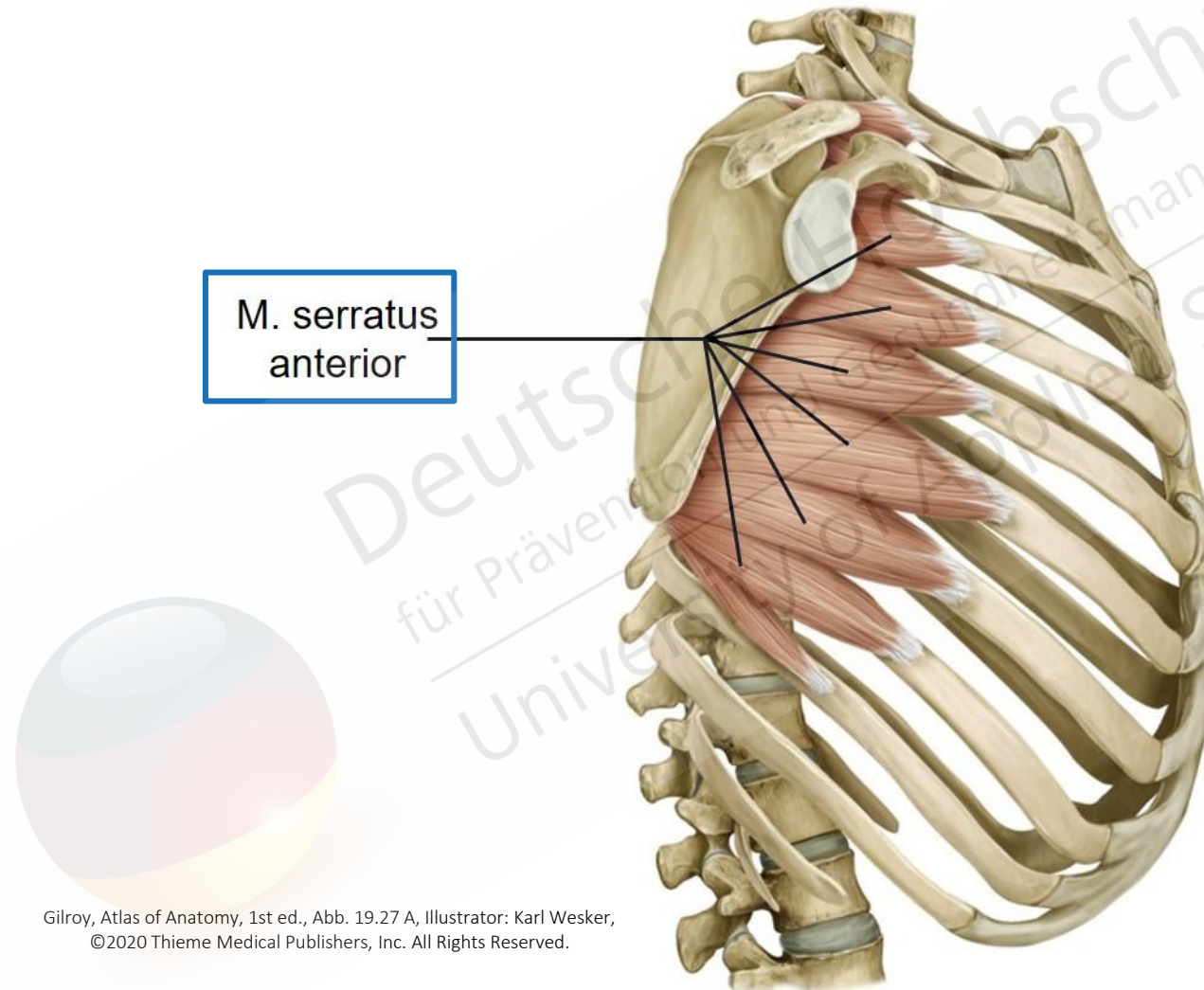
Gilroy, Atlas of Anatomy, 1st ed., Abb. 19.19 A, Illustrator: Karl Wesker,
©2020 Thieme Medical Publishers, Inc. All Rights Reserved.

Muskulatur des Schultergürtels – Ansicht von ventral



Gilroy, Atlas of Anatomy, 1st ed., Abb. 19.19 B, Illustrator: Karl Wesker,
©2020 Thieme Medical Publishers, Inc. All Rights Reserved.

Muskulatur des Schultergürtels – Ansicht von lateral



Gilroy, Atlas of Anatomy, 1st ed., Abb. 19.27 A, Illustrator: Karl Wesker,
©2020 Thieme Medical Publishers, Inc. All Rights Reserved.

Muskulatur des Schultergürtels

Gelenkbewegung:	beteiligte Muskulatur:
Elevation (Hebung)	<ul style="list-style-type: none">• M. trapezius, Pars descendens (Trapezmuskel, absteigender bzw. oberer Anteil)• M. levator scapulae (Schulterblattheber)
Depression (Senkung)	<ul style="list-style-type: none">• M. trapezius, Pars ascendens (Trapezmuskel, aufsteigender bzw. unterer Anteil)• M. pectoralis minor (kleiner Brustmuskel)• M. serratus anterior (vorderer Sägemuskel)
Retraktion (nach dorsal ziehen)	<ul style="list-style-type: none">• M. trapezius, Pars transversa (Trapezmuskel, querverlaufender bzw. mittlerer Anteil)• Mm. rhomboidei (Rautenmuskeln)
Protraktion (nach ventral ziehen)	<ul style="list-style-type: none">• M. pectoralis minor (kleiner Brustmuskel)• M. serratus anterior (vorderer Sägemuskel)